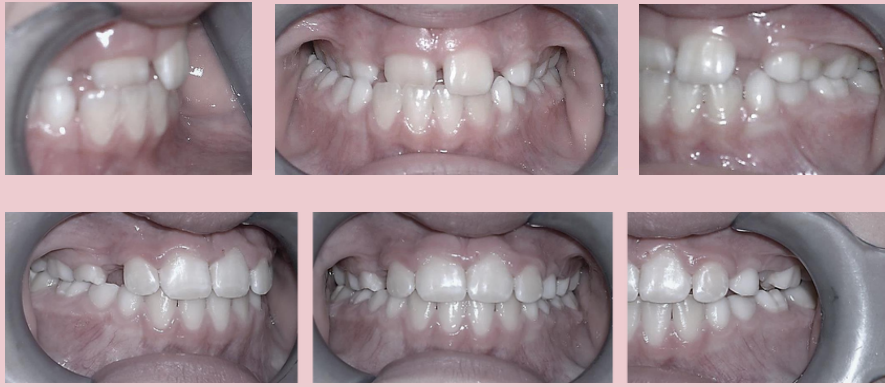
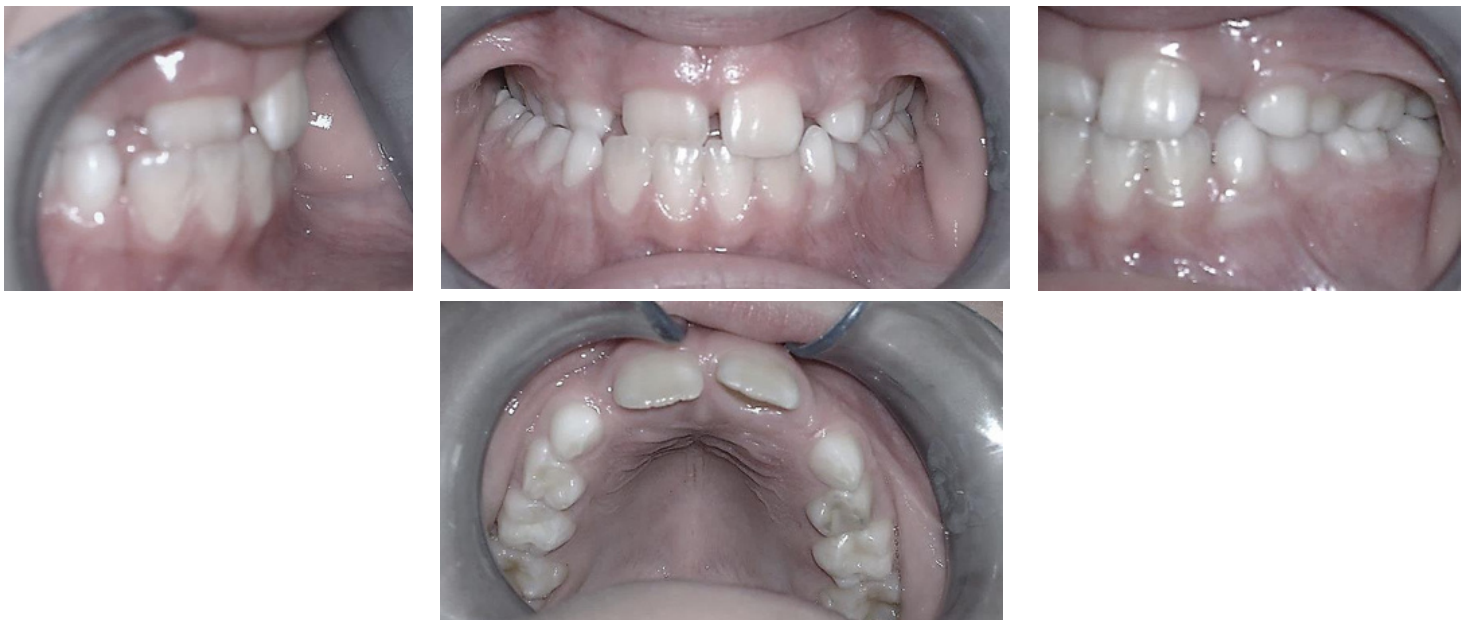
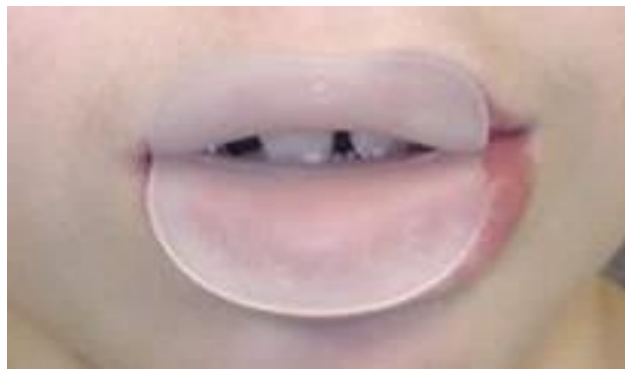**CLASS III RIGHT ANTERIOR
CROSSBITE**

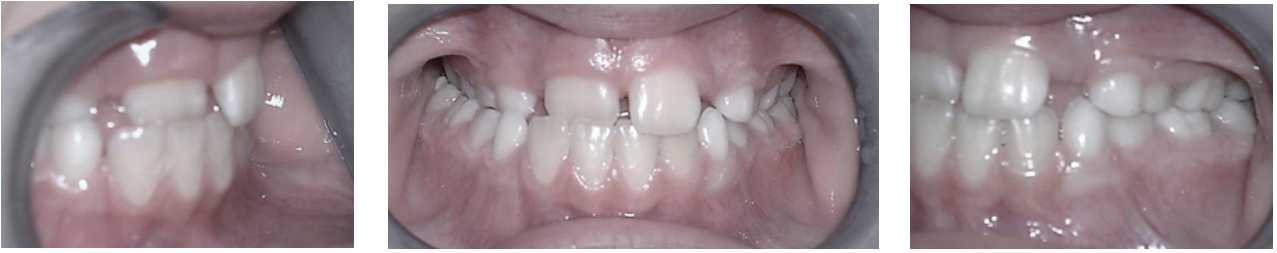Dr. Pietro Manzini



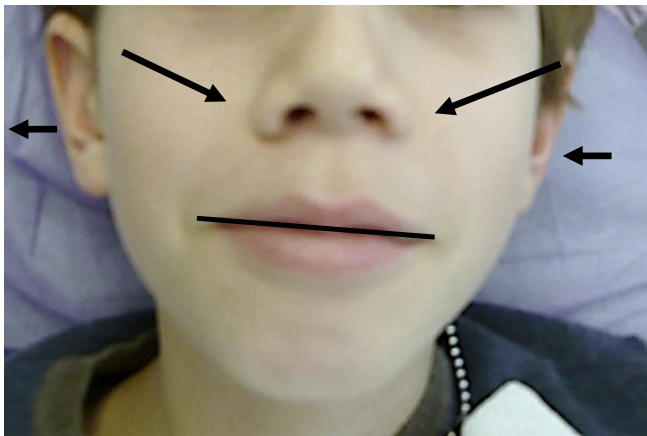
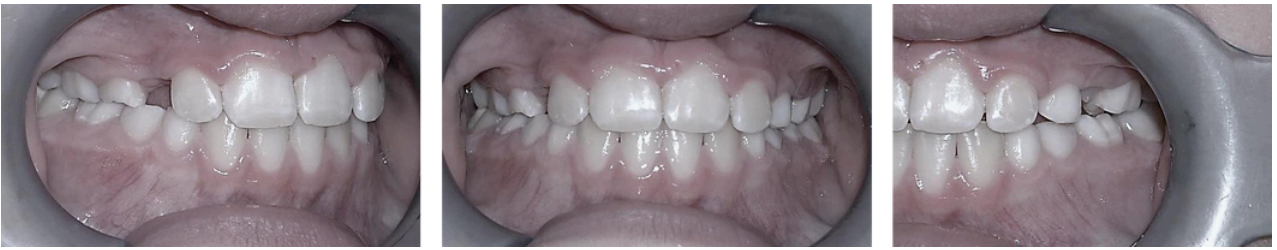THE 7-YEAR-OLD MALE PATIENT PRESENTS A CLASS III ANTERIOR CROSSBITE ON THE RIGHT SIDE AND A "SUCTION-SWALLOWING" TYPE OF DEGLUTITION. THE USE OF FROGGY MOUTH IS PRESCRIBED.



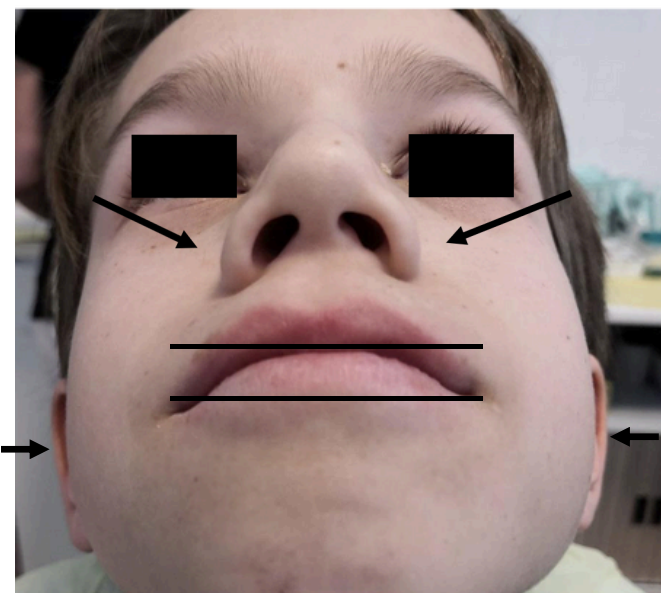
START OF TREATMENT



17 MONTHS LATER



START OF TREATMENT



25 MONTHS LATER



FROGGY MOUTH